Virchows Arch (2006) 449:392–393
DOI 10.1007/s00428-006-0266-6

LETTER TO THE EDITOR

Pulmonary hamartoma associated with typical carcinoid/tumorlet

Alberto Cavazza · Massimiliano Paci · Giulio Rossi

Received: 4 May 2006 / Accepted: 29 June 2006 / Published online: 16 August 2006

Sir,
Pulmonary hamartoma (PH) is a relatively common specimen to be received in the laboratory of Surgical Pathology, and its diagnosis is straightforward in the vast majority of cases. However, some problems may arise when PH is combined with a second neoplasm, a very rare event with a potentially significant impact on prognosis. Both epithelial and mesenchymal tumors have occasionally been described within PH [2, 4]. In this study, we report a hitherto unrecognized association: PH and a bland neuroendocrine proliferation with features of typical carcinoid (TC)/tumorlet.

Our patient was a 65-year-old male, ex-smoker, with an history of left hemicolectomy performed 7 months previously for a moderately differentiated rectal adenocarcinoma (pT3 N1). During the follow-up, a chest X-ray and a computed tomography (CT) scan revealed a well-circumscribed nodule of the lower lobe of the right lung. A videothoracoscopic resection of the nodule was performed. The patient is alive with no evidence of tumor recurrence 6 months after surgery. Grossly, the pulmonary specimen measured 7×3×2 cm and contained a subpleural nodule, 1 cm in diameter, whitish in color, and with pushing margins. Microscopically (Fig. 1), the majority of the tumor had the classical features of PH with lobules of mature cartilage surrounded by fibromyxoid stroma, adipose tissue, and benign epithelial clefts. At the periphery, embedded in the stroma, a second component was present, which extended in the center of the tumor and reached a diameter of 0.6 cm. It consisted of bland epithelioid to spindle cells, with a moderate amount of eosinophilic cytoplasm, “salt and pepper” chromatin and inconspicuous mitotic activity, arranged in anastomosing nodules. No necrosis was evident. The surrounding lung was unremarkable. Immunohistochemically, the cells of the second component were diffusely positive for pan-cytokeratin, chromogranin A, and synaptophysin.

A. Cavazza
Department of Pathology, S. Maria Nuova Hospital,
Reggio Emilia, Italy

M. Paci
Department of Thoracic Surgery, S. Maria Nuova Hospital,
Reggio Emilia, Italy
e-mail: Paci.massimiliano@asmn.re.it

G. Rossi
Section of Anatomic Pathology §, Azienda Policlinico,
Modena, Italy
e-mail: Rossi.giulio@policlinico.mo.it

A. Cavazza (✉)
Unità Operativa di Anatomia Patologica,
Ospedale S. Maria Nuova,
Viale Risorgimento 80,
42100 Reggio Emilia, Italy
e-mail: cavazza.alberto@asmn.re.it

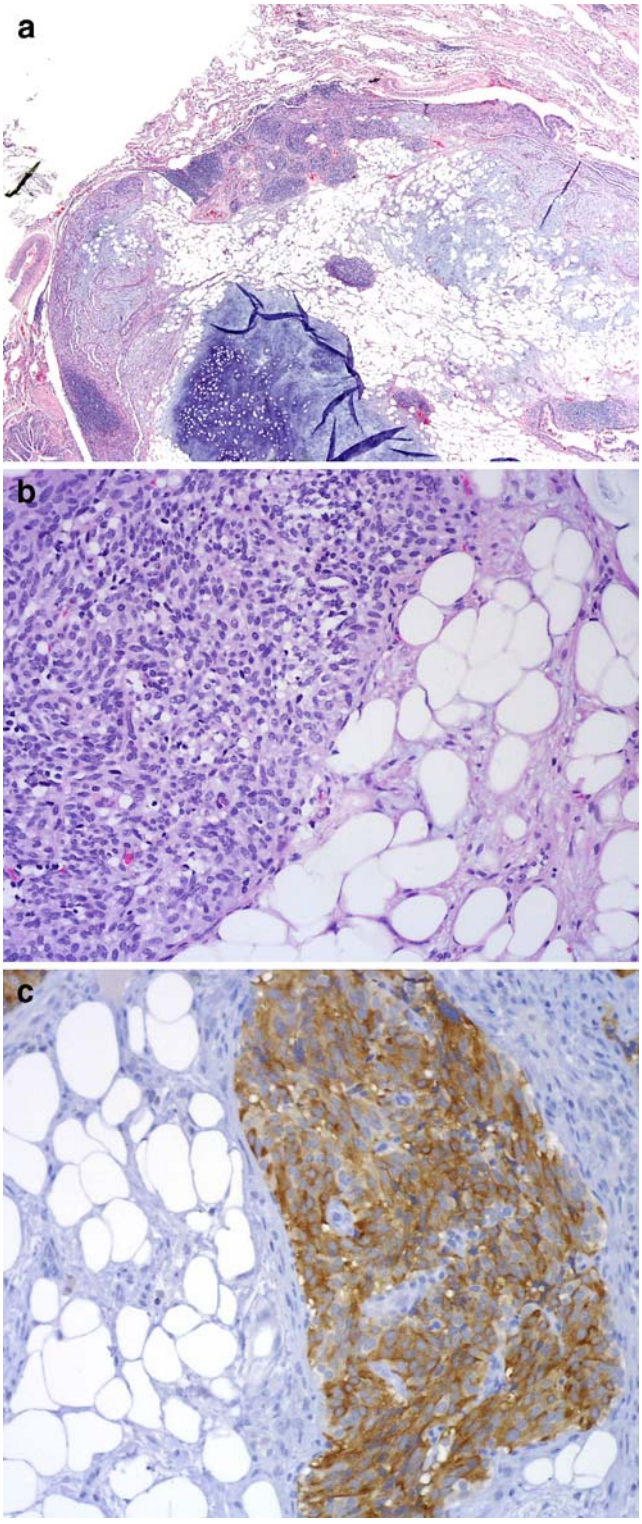

Fig. 1 Neoplastic nodules are embedded in the stroma of a classical pulmonary hamartoma (**a**). The nodules are composed of bland epithelioid to spindle cells (**b**), diffusely immunoreactive with chromogranin A (**c**)

We interpreted this tumor as a TC arising in PH. This interpretation was based on the dimension of the neuroendocrine component (>0.5 cm) [7], but admittedly its multinodular growth made the distinction with a tumorlet quite subjective. This case highlights the need for better criteria to differentiate pulmonary tumorlet from TC. The follow-up of our patient is too brief to be significant; however, the bland morphology of the neuroendocrine component and its small dimension allow to predict a benign clinical behavior.

Although very rare examples of TC combined with acinic cell tumor [3] and adenocarcinoma [1, 5] have been reported in the lung, to the best of our knowledge, this is the first association of TC/tumorlet with PH. General pathologist should be aware that combined PH may rarely occur, to prevent diagnostic mistakes particularly in frozen section [6]. Our observation further expands the spectrum of unusual combinations which can be faced in pulmonary neoplasms.

References

1. Cavazza A, Toffanetti R, Ferrari G, Piana S, Putrino I, Gardini G (2001) Combined neoplasia of the lung: description of a case of adenocarcinoma mixed with typical carcinoid. Pathologica 93: 216–220
2. Pelosi G, Rodriguez J, Viale G, Rosai J (2006) Salivary gland-type tumors with myoepithelial differentiation arising in pulmonary hamartoma. Report of 2 cases of a hitherto unrecognized association. Am J Surg Pathol 30:375–387
3. Rodriguez J, Diment J, Lombardi L, Dominoni F, Tench W, Rosai J (2003) Combined typical carcinoid and acinic cell tumor of the lung: a heretofore unreported occurrence. Hum Pathol 34: 1061–1065
4. Rossi G, Cavazza A, Valli R, Torricelli P, Richeldi L, Rivasi F et al (2003) Atypical lipomatous tumour (lipoma-like liposarcoma) arising in a pulmonary hamartoma and clinically presenting with pneumothorax. Lung Cancer 39:103–106
5. Sen F, Borczuk AC (1998) Combined carcinoid tumor of the lung: a combination of carcinoid and adenocarcinoma. Lung Cancer 21:53–58
6. Sienko A, Allen TC, Zander DS, Cagle PT (2005) Frozen section of lung specimens. Arch Pathol Lab Med 129:1602–1609
7. Travis WD, Brambilla E, Muller-Hermelink HK, Harris CC (2004) Tumours of the lung, pleura, thymus and heart. IARC Press, Lyon, France